

Genomics of Erdheim Chester Disease: Implications for Precision Treatment with Targeted Therapy

Aaron Goodman, MD^{1,2}, Shumei Kato, MD², Michael Y. Choi, MD², and Razelle Kurzrock, MD²

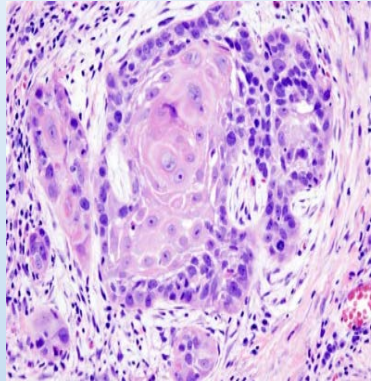
¹Division of Blood and Marrow Transplantation, Moores Cancer Center, UCSD

²Division of Hematology/Oncology, Moores Cancer Center, UCSD

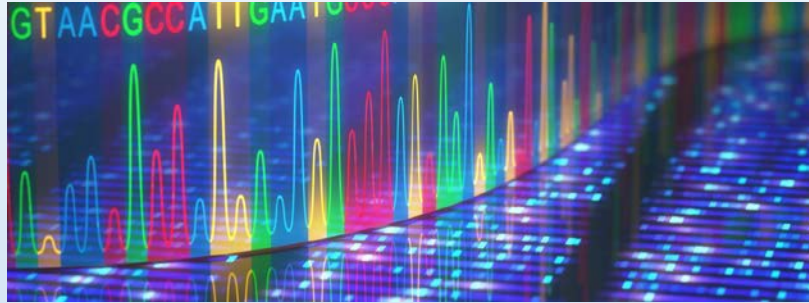
Overview

- Rare tumor clinic at the University of California San Diego
- Our ECD cohort
- Example case
- Conclusions

What we do in Rare Tumor Clinic



Tumor



PREDICT/ IPREDICT Clinical Trial

**“MATCH” the therapy based on the profiling.
Personalized/Precision Medicine approach.**

Comprehensive molecular profiling:

- Next-Generation DNA Sequencing
- Protein analysis
- PD-L1 IHC
- Tumor mutational burden analysis
- Immune signature analysis
- Liquid biopsy (cancer DNA detection from blood)

Molecular Tumor Board

- Initiated December 12, 2012
- Three weeks per month
- Multidisciplinary discussion of patients
- Molecular profiling (clinical-grade) (N ~ 8500)
- Targeted, tailored treatment recommendations



Schwaederle.....Kurzrock, Oncologist, 2014; Parker.....Kurzrock, JOP, 2015

Examples of ultra-rare/rare tumors

Adenoid cystic carcinoma

Ampullary carcinoma

Ameloblastoma

Anal squamous cell carcinoma

Basal cell carcinoma (advanced)

Castleman's disease

Chondrosarcoma

Cholangiocarcinoma

Desmoid tumor

Erdheim–Chester disease

Endometrial stromal sarcoma

Fallopian tube cancer

Liposarcoma

Metaplastic carcinoma of breast

Merkel cell carcinoma

Myxofibrosarcoma

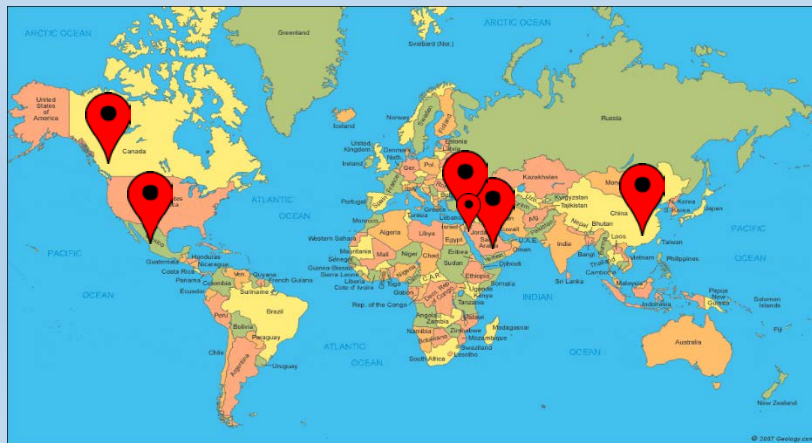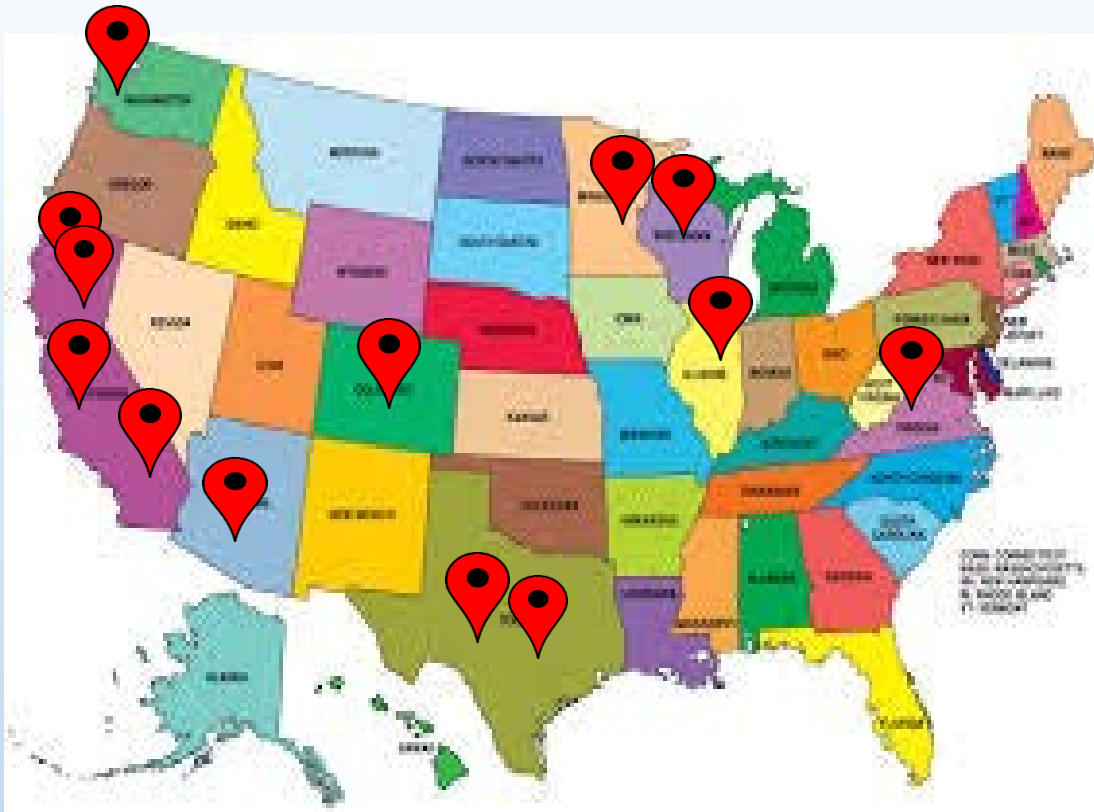Neuroendocrine tumor of the uterine cervix

Ocular melanoma

Papillary ovarian cancer

Thymoma, type B3

Yolk sac tumor of the liver



Rare Hematologic Malignancy Clinic

- Erdheim Chester disease (N = 9)
- Langerhans cell histiocytosis
- Castleman disease (unicentric and multicentric)
- Amyloidosis
- Schnitzler's syndrome
- Extraosseous IgA plasmacytoma
- Chronic natural killer cell lymphocytosis

UCSD ECD Cohort (N = 6)

Male (%)	4 (67%)
Female (%)	2 (33%)
Median age in years at diagnosis (range)	52 (33-64)
Median number of prior therapies (range)	3 (1-4)
ECD Classification	
CNS dominant (%)	1 (17%)
Orbital-craniofacial dominant (%)	4 (67%)
Cardiac dominant (%)	1 (17%)

Patient	Sex	Age at diagnosis (years)	ECD classification	BRAF V600E status	Prior treatment(s)
1	F	49	CNS dominant	Positive	Cyclophosphamide Vemurafenib Imatinib
2	M	56	Orbital-craniofacial dominant	Positive	Methotrexate Cyclophosphamide Cladribine
3	F	64	Cardiac dominant	Negative	Cladribine
4	M	52	Orbital-craniofacial dominant	Positive	N/A
5	M	52	Orbital-craniofacial dominant	Positive	Vemurafenib Dabrafenib Trametinib
6	M	33	Orbital-craniofacial dominant	Negative	Interferon

Genomic profiling including tissue PCR, NGS, and ctDNA*

- Tissue CGP was performed in four patients.
- Plasma targeted NGS (ctDNA) was performed on all 6 patients.
- Four patients were tissue *BRAF V600E*-positive

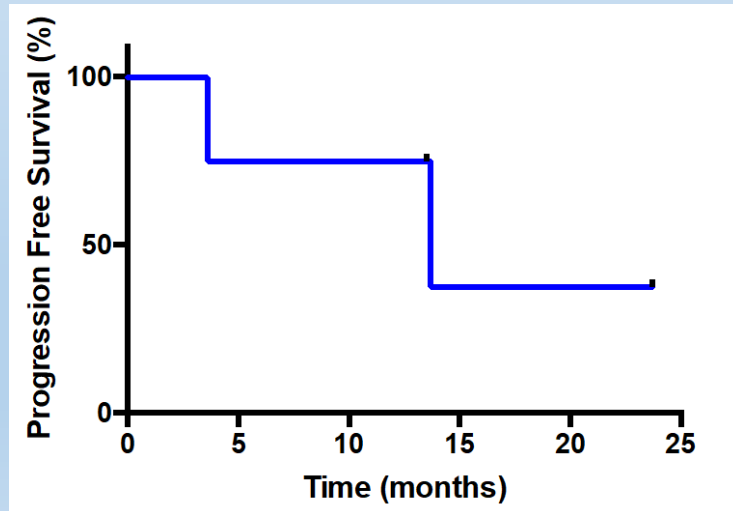
*Patients included in Janku.....Kurzrock. Clinical and molecular profiling.....ECD International symposium, Oct 26. 2017

Genomics	
<i>BRAF V600 E</i> positive (%)	4 (67%)
<i>NF1</i> positive (%)	3 (50%)
Median number (range) of alterations detected in CGP of tissue (N = 4)	1 (0-3)
Median number (range) of alteration detected in cell free DNA (N = 6)	1 (0-3)

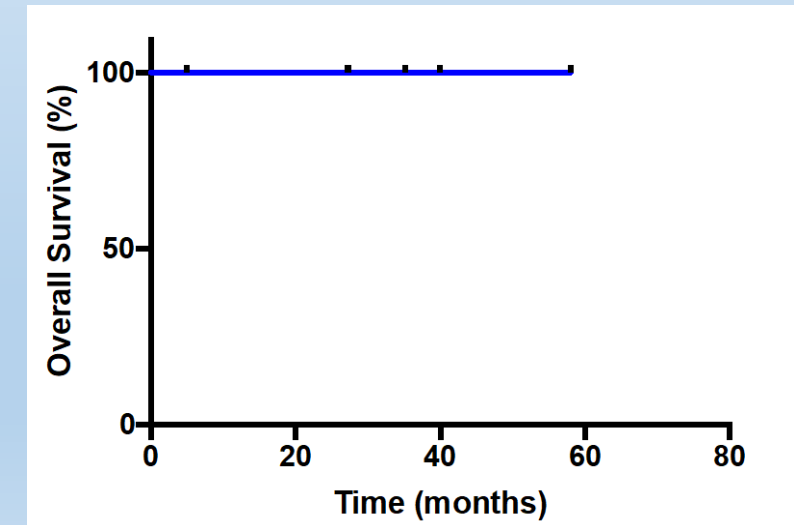
Patient	Tissue PCR	Tissue targeted NGS	Plasma targeted NGS
1	<i>BRAF V600E</i>	Not done	<i>NF1</i> H1494Y
2	<i>BRAF V600E</i>	No alterations identified	None
3	Not done	Failed	<i>FGFR2</i> V274I
4	<i>BRAF V600E</i>	No alterations identified	None
5	Not done	<i>BRAF V600E</i> <i>ASXL1</i> R693 <i>U2AF1</i> Q	<i>JAK2</i> V617F <i>NF1</i> S1407R <i>NRAS</i> G60R
6	Not done	<i>CD36</i> L360*	<i>NF1</i> I679fs

Treatment

Median number (range) of treatments	3 (1-4)
Number of patients treated with a BRAF inhibitor (%)	4 (67%)
Number of patients who responded (PR/CR) to a BRAF inhibitor	3 (75%)
Number of patients who discontinued BRAF inhibitor due to toxicity	2 (33%)
Number of patients treated with MEK inhibitor (trametinib)	2 (33%)
Median PFS (range) to BRAF inhibitor (range)	13.7 (3.6 to 23.7+) months
Median OS (range) since diagnosis (range)	Not reached (5.0+ to 58.0+)



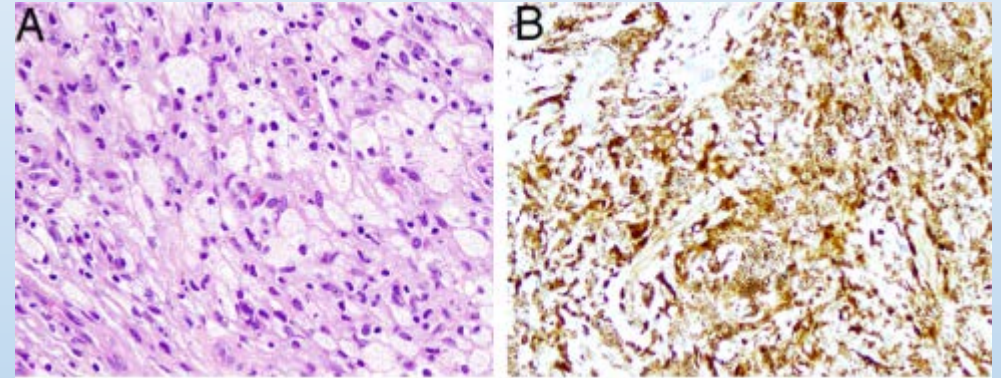
Progression free survival for the 4 patients treated with BRAF inhibitors.



Overall survival (Panel B) for the entire cohort of 6 patients

Patient # 5

- 52 year-old male who initially presented with eye swelling and a retro-orbital mass.
- Biopsy of mass consisting of CD68 positive foamy histiocytes and he was diagnosed with orbital craniofacial dominant ECD.
- Tissue NGS revealed a ***BRAF V600E*** alteration. In addition *ASXL1* R693* and *U2AF1* Q157P alterations were identified.
- Analysis of ctDNA revealed a *JAK2* V617F (2.9%) alteration. This was thought to be an “incidental” finding as his blood counts were normal and he had no splenomegaly.

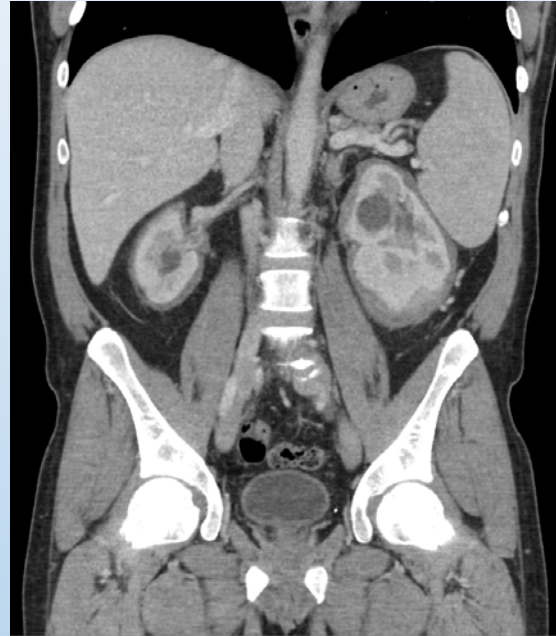


Numerous bland foamy histiocytes staining positive by IHC for 6d68 (B).

Patient 5

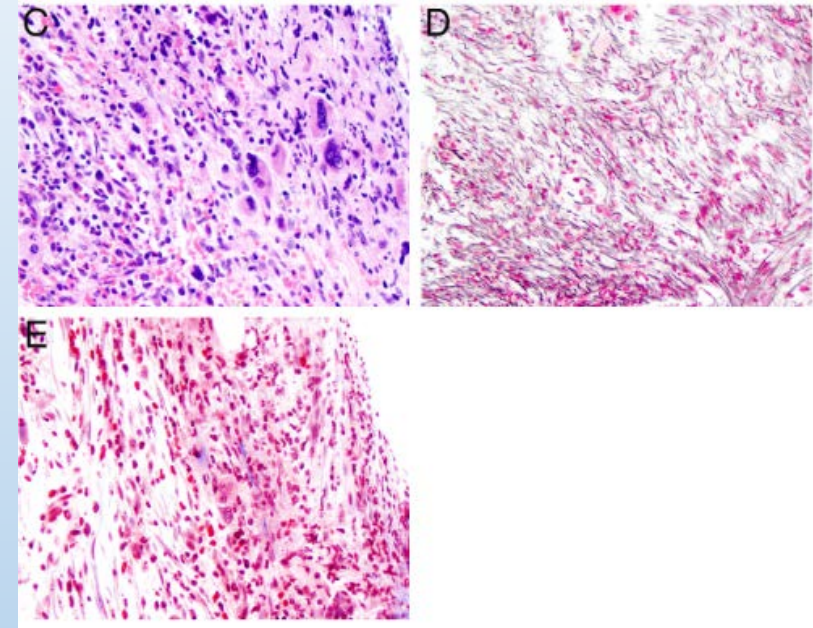
- Treated with dabrafenib, vemurafenib, and trametinib
 - All discontinued due to poor tolerability (arthralgias and uveitis), despite dose reductions.
- Pegylated interferon alfa-2b, with ongoing stable disease at 20+ months.
- 13 months after the ctDNA test with *JAK2 V617F*, he developed anemia, thrombocytopenia, and splenomegaly.
- Marrow biopsy showed megakaryocytic atypia and markedly increased marrow fibrosis consistent with myelofibrosis. There was no increase of myeloid blasts.

CT AP



Spleen measuring 16 cm

Bone marrow biopsy



Reticulin (D) and Trichrome (E)

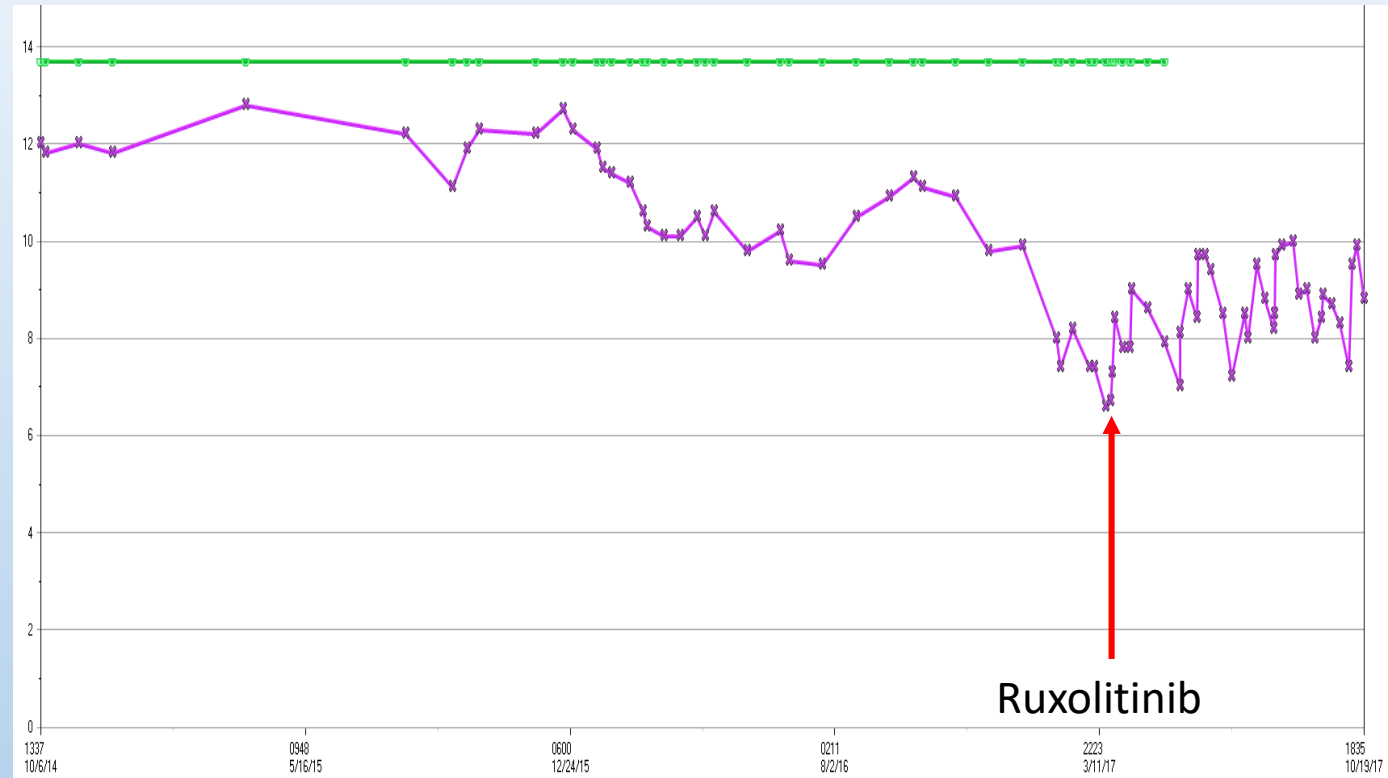
Summary of Genomics for Patient 5

Date of Assessment:	May 2014	December 2015	April 2017
Source for NGS:	Orbital mass	Blood (ctDNA)	Blood (ctDNA)
NGS results:	<i>ASXL1</i> R693* <i>U2AF1</i> Q157P <i>BRAF</i> V600E	<i>JAK2</i> V617F (2.9%)	<i>RIT1</i> M90V (4.0%) <i>JAK2</i> V617F (3.2%) <i>BRAF</i> V600E (0.06%) <i>KRAS</i> A59T (2.9 %)
Intervention:	None	Vemurafenib followed by trametinib	Interferon alfa-2b
Status of ECD		Stable disease	Stable disease
Status of myelofibrosis	Not clinically apparent: No anemia or thrombocytopenia	Not clinically apparent	WHO grade 2 myelofibrosis. Hgb 7.5, Platelet count 70

Patient 5

- He started ruxolitinib (JAK2 inhibitor) in April of 2017 with his dose titrated from 5 mg daily to 10 mg BID.
- His hemoglobin is slowly starting to increase.
- His splenomegaly resolved.
- His ECD remains stable on INF.

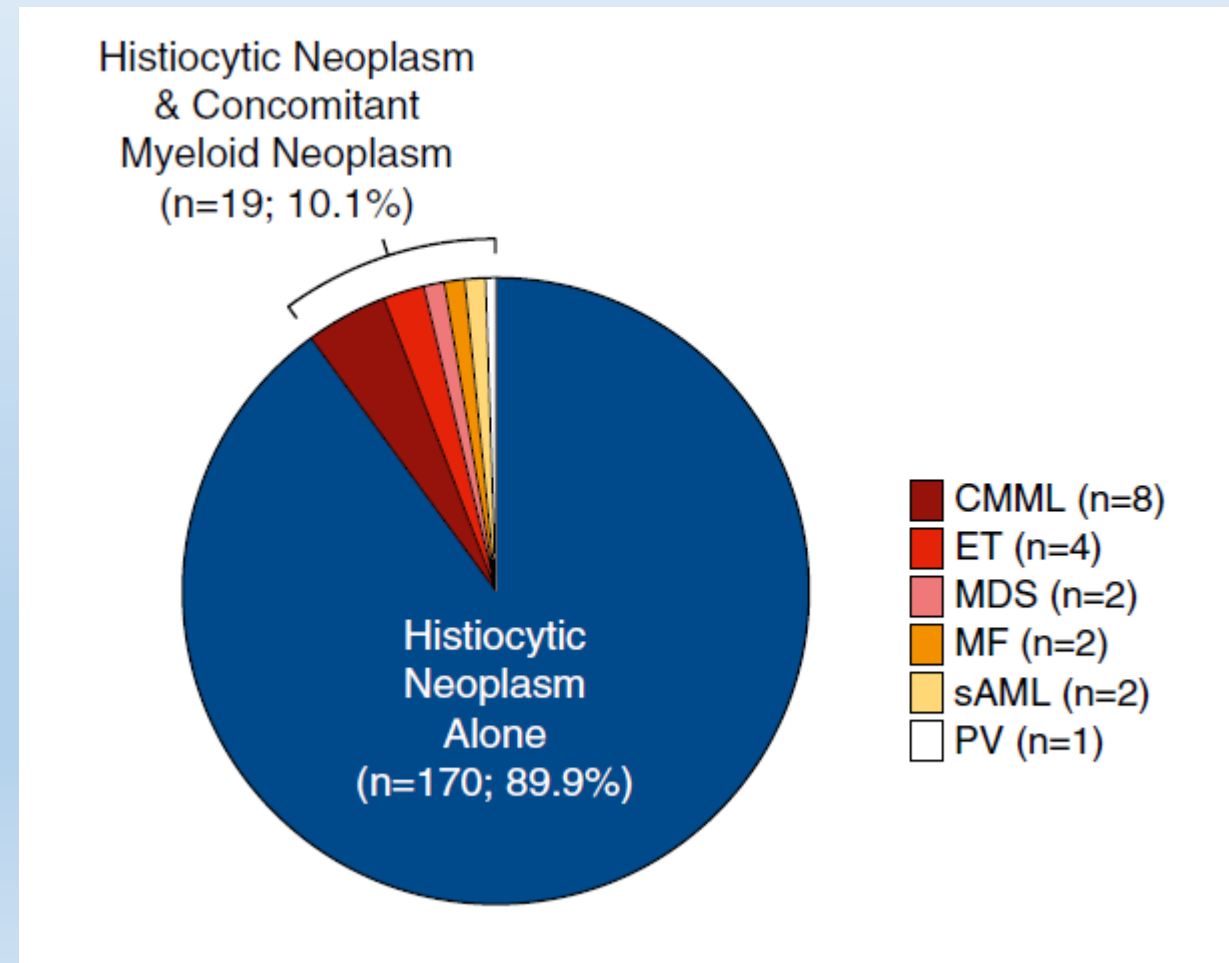
Hemoglobin (g/dl) trend



High prevalence of myeloid neoplasms in adults with non-Langerhans cell histiocytosis

Matthias Papo,^{1,*} Eli L. Diamond,^{2,*} Fleur Cohen-Aubart,^{1,*} Jean-François Emile,^{3,4} Damien Roos-Weil,⁵ Nishant Gupta,⁶ Benjamin H. Durham,⁷ Neval Ozkaya,⁷ Ahmet Dogan,⁷ Gary A. Ulaner,⁸ Raajit Rampal,⁹ Jean-Emmanuel Kahn,¹⁰ Thomas Sené,¹¹ Frédéric Charlotte,¹² Baptiste Hervier,¹³ Caroline Besnard,¹ Olivier A. Bernard,⁵ Catherine Settegrana,¹⁴ Nathalie Droin,¹⁵ Zofia Hélias-Rodzewicz,^{3,4} Zahir Amoura,¹ Omar Abdel-Wahab,^{9,16,*} and Julien Haroche^{1,*}

- 10.1% of adults with non-Langerhans cell histiocytosis have a concomitant myeloid neoplasm with each often harboring distinct mutations.
- Mutations were identified in JAK2, CALR, TET2, ASXL1, IDH2, U2AF1, and TP53.
- **Our data suggests that these mutations can be picked up by ctDNA prior to development of an overt myeloid neoplasm.**



In summary

- Patients with ECD by tissue and blood-derived ctDNA may provide information for choosing targeted therapy in both *BRAF* V600E-mutated and wildtype patients.
- ctDNA was able to identify alterations that were not found by tissue NGS.
- In one ECD patient, ctDNA-derived *JAK2* V617F was an early harbinger of myelofibrosis, which manifested clinically one year later.

Thankyou!

- Our patients
- Collaborators at UCSD
 - Shumei Kato, MD
 - Mike Choi, MD
 - Razelle Kurzrock, MD
- ECD symposium team for hosting this wonderful conference